ORIGINAL ARTICLE

Odontogenic Sinusitis: Where to Start? The Importance of a Multidisciplinary Approach

Candelaria Serrano[1], Facundo Zamar[2] and Sebastián Aragón[1]

1. Department of Otolaryngology, Hospital Italiano. Buenos Aires, Argentina

2. Department of General Surgery, Hospital Italiano. Buenos Aires, Argentina

ABSTRACT

Introduction: odontogenic sinusitis can be secondary to an adjacent infectious dental pathology or iatrogenic lesions resulting from dental procedures. It accounts for up to 75 % of cases of unilateral maxillary sinus opacification seen in computed tomography. There is a lack of clear consensus regarding the optimal management and the appropriate timing for interventions. The goal is to propose an approach centered on active collaboration between the Otolaryngology and Maxillofacial services and present the action algorithm used.

Materials and methods: retrospective descriptive study of patients with odontogenic sinusitis who received a multidisciplinary approach and combined surgery.

Results: 21 patients underwent combined surgery for dental and nasal treatment. All patients underwent combined surgery. Nasal surgery was performed endoscopically with maxillary antrostomy based on the opacification seen in the computed tomography. In the dental aspect, the affected teeth and odontogenic cysts were removed. Oral-antral communications and fistulas were closed with flaps during the same surgical procedure. All patients resolved without complications.

Discussion: if the origin is a treatable dental infection, the initial approach should include specific dental treatment alongside medical management. There are indications for early endoscopic surgery, such as impact on quality of life or risk of complications. Notably, when both the dental pathology and sinusitis are addressed, a resolution rate of 90 % can be expected, with early symptomatic improvement of the sinus. In our experience, we prefer to perform combined treatment when it is not feasible to treat the dental pathology conservatively and when the responsible dental piece or implant needs to be extracted.

Conclusion: we believe that close collaboration between specialists is essential to achieve optimal outcomes. When surgical intervention is indicated in both fields, simultaneous combined surgery represents a direct, reliable, and curative strategy, with low morbidity, a low incidence of complications, and rapid recovery.

Keywords: sinusitis, dental infection, otolaryngology, endoscopic nasal surgery, maxillofacial surgery.

Sinusitis odontógena: ¿por dónde empezar? La importancia del abordaje multidisciplinario

RESUMEN

Introducción: la sinusitis odontógena puede ser secundaria a una patología infecciosa dental adyacente o a lesiones iatrogénicas derivadas de procedimientos dentales. Representa hasta el 75% de los casos

Corresponding author: candelaria.serrano@hospitalitaliano.org.ar, Serrano C.

Received: 2/23/2026 | Accepted: 08/10/2026 | Published: 9/18/2026

DOI: http://doi.org/10.51987/Rev.Hosp.Ital.B.Aires.v46i3.1318

How to cite: Candelaria S, Zamar F, Aragón S. Sinusitis odontógena: ¿por dónde empezar? La importancia del abordaje multidisciplinario. Rev Hosp Ital B.Aires. 2026;46(3):e0001318

BY-NC-SA 4.0
ISSN (en línea) 2314-3312

de opacificación unilateral de seno maxilar por tomografía computarizada. Existe una falta de consenso claro con respecto al manejo óptimo y el momento adecuado para las intervenciones. El objetivo es proponer un enfoque centrado en la colaboración activa entre los Servicios de Otorrinolaringología y Maxilofacial y presentar el algoritmo de acción utilizado.

Materiales y métodos: estudio descriptivo retrospectivo de pacientes con sinusitis odontógena que recibieron abordaje multidisciplinario y cirugía combinada.

Resultados: veintiún (21) pacientes fueron sometidos a cirugía combinada para tratamiento odontológico y nasal. A la altura sinusal se realizó cirugía endoscópica nasal con antrostomía maxilar según ocupación evidenciada por tomografía computarizada. A nivel dentario, las piezas dentarias afectadas fueron removidas, al igual que los quistes odontogénicos. La comunicación y las fístulas oroantrales fueron cerradas con colgajos en el mismo tiempo quirúrgico. Todos los pacientes resolvieron sin complicaciones.

Discusión: si el origen es una infección dental tratable, el abordaje inicial debe incluir tratamiento odontológico específico en conjunto con manejo médico. Existen indicaciones de cirugía endoscópica temprana como impacto en la calidad de vida o riesgo de complicaciones. Es notable que cuando se abordan tanto la patología dental como la sinusitis, puede esperarse una resolución del cuadro en el 90%, con una mejoría sintomática sinusal temprana. En nuestra experiencia, preferimos realizar el tratamiento combinado cuando no es factible tratar la patología dental de forma conservadora y cuando es necesario extraer la pieza dental o el implante responsable.

Conclusión: consideramos que la colaboración estrecha entre especialistas es fundamental para alcanzar resultados óptimos. Cuando está indicada la intervención quirúrgica en ambos campos, la cirugía combinada simultánea representa una estrategia directa, fiable y curativa, con baja morbilidad, baja incidencia de complicaciones y recuperación rápida.

Palabras clave: sinusitis, infección focal dental, otorrinolaringología, cirugía endoscópica nasal, cirugía maxilofacial.

INTRODUCTION

Odontogenic sinusitis may result from an adjacent dental infection or from iatrogenic injury associated with dental procedures. It accounts for approximately 25% to 40% of all cases of chronic maxillary sinusitis and for 45% to 75% of cases of unilateral maxillary sinus opacification on computed tomography (CT).[1] Diagnosis may be challenging because sinonasal symptoms are nonspecific and dental symptoms are often minimal.

Potential dental conditions include apical periodontitis (endodontic disease resulting from pulp necrosis), marginal periodontitis, oroantral communication or fistula (OAC or OAF), and foreign bodies within the maxillary sinus related to dental treatment. Otolaryngologists should confirm sinusitis by nasal endoscopy, assessing for pus in the middle meatus, edema, or polyps, and by CT of the craniofacial region. Dental professionals should confirm dental disease through appropriate examinations and imaging studies, such as panoramic radiography.[2]

Currently, there is no clear consensus regarding the optimal management or timing of surgical intervention for odontogenic sinusitis. The literature shows considerable variability in the indications, sequence, and timing of dental and otolaryngologic interventions, resulting in heterogeneous and, at times, suboptimal clinical practice. In contemporary clinical practice, identifying, understanding, and appropriately managing odontogenic sinusitis is essential to achieve optimal patient outcomes.

The aim of this study is to propose an approach centered on active collaboration between the Otolaryngology and Maxillofacial Surgery Departments to ensure comprehensive assessment, appropriate treatment planning, and timely intervention. We present the management algorithm developed at a private hospital in Buenos Aires, which standardizes the diagnostic and therapeutic approach to optimize clinical outcomes and reduce the risk of recurrence.

OBJECTIVE

To evaluate the outcomes of odontogenic sinusitis treatment using an approach centered on active collaboration between the Otolaryngology and Maxillofacial Surgery Departments.

MATERIALES Y MÉTODOS

We conducted a retrospective descriptive study of patients with odontogenic sinusitis who underwent

multidisciplinary management and combined surgery. We collected demographic variables (sex and age), extent of sinus involvement (according to the Lund-Mackay CT score), odontogenic etiology, and treatment performed (dental procedure and endoscopic sinus surgery). We used descriptive statistics to characterize the study population. Categorical variables are reported as relative frequencies and/or percentages, whereas quantitative variables are expressed as mean and standard deviation or median and interquartile range (IQR), according to the distribution of the data. Statistical analyses were performed using Stata, version 16.

The study protocol was approved by the institutional Ethics Committee (CEPI #7717; PRIISA #18150) and conducted in accordance with the principles of the amended Declaration of Helsinki.

RESULTS

Twenty-one patients underwent combined surgery for dental and sinonasal treatment. Eleven were women and 10 were men, with a mean age of 55 years. In 71% of cases (15 patients), the odontogenic cause was infection involving a tooth with periradicular disease. Of these, three patients had an oroantral communication evident on CT. Of the remaining patients, three had odontogenic cysts and three developed sinus disease following tooth extraction, with a post-extraction oroantral fistula. The left maxillary sinus was the most frequently affected; however, the original data indicate that 12 patients had right maxillary sinusitis.

All patients underwent combined surgery. For sinonasal treatment, endoscopic sinus surgery (ESS) with maxillary antrostomy was performed according to the extent of sinus opacification observed on CT. The affected teeth and odontogenic cysts were removed. Oroantral communications or defects resulting from tooth extraction during surgery were closed with a buccal advancement flap. Chronic oroantral fistulas were closed using double-layer flaps (marginal flap plus buccal fat pad or marginal flap plus buccal flap). All procedures were performed on an outpatient basis by the same surgical team. All patients achieved symptom resolution without complications (Table 1).

DISCUSSION

According to its etiology, the dental source may be classified as endodontic, periodontal, endodontic-periodontal, or other. Endodontic causes include pulp necrosis, periapical inflammation, root fracture, and other infections of endodontic origin. Periodontal causes include periodontal defects associated with severe alveolar bone resorption. Endodontic-periodontal lesions involve teeth affected by a combined infection of endodontic and periodontal origin. Other causes include oroantral fistulas or foreign bodies displaced into the maxillary sinus during tooth extraction or other oral surgical procedures (Figs. 1, 2, and 3). The proximity of the tooth roots to the floor of the maxillary sinus creates a close anatomical relationship. Disease involving these structures may disrupt the sinus membrane, providing a pathway for bacteria, foreign material, and inflammatory mediators to enter the sinus cavity. This process triggers mucosal inflammation and impairs mucociliary clearance and, if left untreated, may eventually spread to involve all paranasal sinuses. Collaboration with dental specialists is essential; panoramic radiography and computed tomography can reveal subtle periapical disease responsible for sinusitis.[3]

Odontogenic sinusitis tends to be overlooked or misdiagnosed. Some cases may even be asymptomatic, with no dental or sinonasal symptoms. Turfe et al. analyzed patients with unilateral sinus disease and found that 44% reported foul-smelling nasal discharge and 87% had purulent material in the middle meatus.[4] Otolaryngologists should refer patients with unilateral maxillary sinus opacification to dental specialists for evaluation of potential dental disease, even when CT does not reveal any apparent dental abnormalities.[3]

In addition, the importance of dental treatment is often underestimated, and endoscopic sinus surgery (ESS) is frequently performed when antibiotic therapy fails to achieve clinical improvement. However, when sinusitis originates from a treatable dental infection, such as deep caries, a periapical abscess, or pulp necrosis, initial management should include specific dental treatment together with medical therapy (antibiotics, oral hygiene measures, and local treatment). Several studies have shown that a substantial proportion of these cases may resolve without the need for sinus surgery. In one study of 33 patients,[5] 22 (67%) achieved resolution with medical and dental treatment, whereas 11 (33%) required ESS after dental and medical treatment failed to resolve the sinusitis.

One of the most common causes is endodontic infection, which originates from pulp necrosis and extends through the root canals into the surrounding supporting tissues, resulting in apical periodontitis. It is most commonly managed with root canal treatment (endodontic treatment), which may resolve both the periodontitis and sinusitis. Endodontic treatment preserves the natural dentition; however, the complex anatomy of the root canal system requires specialized microsurgical techniques and appropriate instrumentation to optimize technical success. Subsequent coronal restorations must provide an effective seal to prevent leakage and recontamination of the endodontic space. However, there is stronger evidence supporting the effectiveness of tooth extraction in the treatment of odontogenic sinusitis, as pulpal and periapical disease can be completely eradicated by removing the affected tooth.[6]

Earlier surgical intervention should be considered in patients with severe sinonasal symptoms that significantly impair quality of life, extension of disease beyond the paranasal sinuses, or a risk of complications.[1] When inflammation from maxillary sinusitis spreads, infection may extend from the maxillary sinus to the facial, periorbital, and intraorbital soft tissues and even to the cavernous sinus or intracranial compartment. This

Table 1. Demographic characteristics, diagnosis, and treatment of the series

Patient N.º	Sex	Age	Sinus disease	Dental disease	Treatment
1	F	55	Left maxillary and ethmoid sinus disease	Tooth 26 + apical cyst involving the sinus floor	ESS + tooth extraction, closure of the oroantral communication, and bone grafting for alveolar preservation
2	M	30	Left maxillary sinus disease	Tooth 26	ESS + extraction of tooth 26 + closure of the oroantral communication
3	F	35	Left maxillary sinus disease	Tooth 26	ESS + extraction of tooth 26 + buccal advancement flap for closure of the oroantral communication
4	F	62	Right maxillary sinus disease	Retained molar roots	ESS + extraction of tooth 17 + buccal advancement flap
5	F	81	Right maxillary sinus disease	Tooth 16	ESS + extraction of tooth 16 + buccal advancement flap
6	M	78	Right maxillary sinus disease	Post-extraction oroantral communication at tooth 18 site	ESS + buccal fat pad flap + buccal advancement flap
7	M	38	Left maxillary and ethmoid sinus disease	Tooth 26	ESS + extraction of tooth 26 + buccal advancement flap
8	F	48	Left maxillary sinus disease	Tooth 25	ESS + extraction of tooth 25 + buccal advancement flap
9	F	44	Left maxillary sinus disease + right maxillary sinus disease + maxillary cyst	Tooth 27 + oroantral fistula	ESS + extraction of tooth 27 + buccal advancement flap
10	F	25	Left maxillary sinus disease	Impacted right maxillary third molar	ESS + extraction of teeth 18 and 19
11	M	30	Left maxillary sinus disease	Left maxillary second molar in poor condition	ESS + extraction of teeth 27 and 28 + buccal advancement flap
12	M	67	Left maxillary sinus disease	Two odontogenic foci in the area, with imaging findings consistent with a small oroantral fistula	ESS + extraction of teeth 26 and 27 + buccal advancement flap
13	F	59	Left maxillary sinus disease	Retained root of a left maxillary molar	ESS + extraction of teeth 24 and 27 + buccal advancement flap
14	F	65	Left maxillary sinus disease	Post-extraction oroantral fistula	ESS + fistula closure with marginal and buccal advancement flaps
15	M	76	Right maxillary sinus disease	Tooth 17 with periradicular infection	ESS + extraction of tooth 17 + buccal flap closure
16	M	58	Right maxillary sinus disease	Odontogenic keratocyst	ESS + resection + buccal flap closure
17	M	84	Right maxillary sinus disease	Tooth 18 with a periapical cyst	ESS + extraction of tooth 18 + buccal advancement flap
18	F	72	Left maxillary sinus disease	Tooth 26	ESS + extraction of tooth 26 + buccal advancement flap
19	M	59	Right maxillary sinus disease	Dental bridge involving teeth 17 and 15, with associated mobility and loss of apical-periapical bone continuity	ESS + extraction of teeth 17 and 15
20	F	61	Right maxillary sinus disease + fistula	Post-extraction oroantral fistula	ESS + closure with marginal and buccal advancement flaps
21	M	45	Left maxillary sinus disease	Teeth 27 and 28	ESS + extraction of teeth 27 and 28 + buccal flap closure

Figure 1. Noncontrast CT of the craniofacial region. Coronal view showing a periapical lytic lesion affecting the right maxillary second molar, with right maxillary sinus disease.

Figure 2. Noncontrast CT of the craniofacial region. Coronal view showing a periradicular cystic lesion associated with the maxillary second molar, with an oroantral communication and left maxillary sinus disease.

may result in facial cellulitis, orbital cellulitis, orbital abscess, cavernous sinus thrombophlebitis, or intracranial infection.[3]

Smoking and a high Lund-Mackay score may be considered predictors of a poor response to antibiotic therapy; therefore, earlier ESS may be indicated in these patients.[7]

Particularly in cases of sinusitis associated with dental implants, ESS as primary treatment has shown a higher success rate than implant removal. Removal of healthy osseointegrated implants may not be necessary unless peri-implantitis or implant mobility is present.[1] Whenever possible, ESS should aim to preserve the dental implant.

Notably, when both the dental disease and sinusitis are treated, resolution can be expected in 90% to 100% of cases, with early improvement in sinonasal symptoms.[1] In a prospective study of 37 patients, Craig et al. showed that patients who underwent endoscopic sinus surgery experienced significantly faster resolution of sinusitis symptoms and endoscopic findings, within 7 to 12 days, compared with those initially treated with root canal treatment or tooth extraction, in whom resolution took 35 to 56 days.

There is no doubt that both rhinologic and dental treatment are necessary; however, the optimal sequence and timing remain controversial. We consider combined surgery to be the preferred treatment approach, with functional endoscopic sinus surgery and an intraoral procedure performed during the same surgical session. Several studies have reported success rates of up to 97% with a combined approach including ESS.[2-8]

In our experience, we prefer combined treatment when conservative management of the dental disease is not feasible and extraction of the causative tooth or removal of the responsible implant is required, with the consequent risk of creating an oroantral communication.

When a dentist extracts a tooth or implant in the presence of active sinusitis, the possibility of an oroantral communication should be considered. If not adequately managed, the communication may develop into an oroantral fistula. In these cases, immediate flap closure

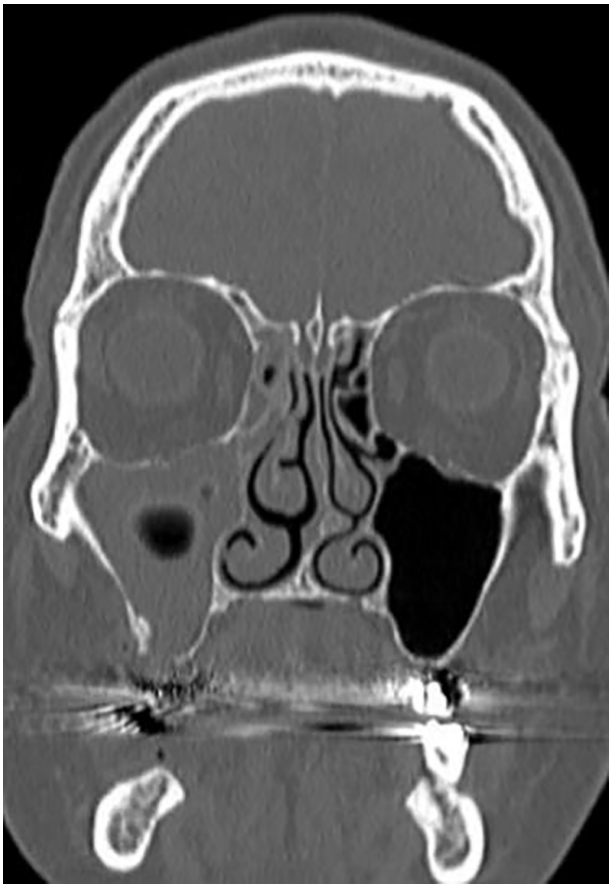

Figure 3. Noncontrast CT of the craniofacial region. Coronal view showing an oroantral communication following extraction of tooth 18, with right maxillary sinus disease.

without first assessing the status of the ostiomeatal complex (OMC) may significantly increase the risk of impaired healing and fistula formation. The incidence of fistula may be higher when extractions are performed in the setting of acute sinusitis with pus draining through the communication. Therefore, it could be argued that performing ESS as primary treatment may help reduce the risk of oroantral communication and fistula by treating the maxillary sinus infection beforehand. As other authors have shown, closure of the communication is significantly more likely to succeed when OMC patency has been restored.[8] This provides an additional rationale for performing the procedures during the same surgical session (ESS, tooth extraction, and closure of the communication).

Oroantral communications are usually closed surgically, depending on their size, using a variety of techniques.[9] Suturing the surrounding gingiva may provide effective closure for defects smaller than 5 mm, whereas a flap procedure is recommended when the fistulous opening is larger than 5 mm. The most widely used local flap techniques include the buccal advancement flap, buccal fat pad (Bichat's fat pad) flap, and palatal rotational flap.[10]

The buccal advancement flap involves designing a broad-based trapezoidal mucoperiosteal flap, which is advanced over the defect and sutured in place. The technique is straightforward to perform, and the literature has reported high flap survival rates. The buccal fat pad flap is created through a vestibular incision, followed by blunt dissection and gentle advancement of the fat pad toward the recipient site. Its advantages include the possibility of double-layer closure and complete coverage by the oral mucosa. Its rich blood supply allows the exposed fat to undergo spontaneous epithelialization. Finally, the palatal flap is thicker and therefore less susceptible to tearing; however, its rigidity makes it more difficult to manipulate, and it is usually associated with greater postoperative pain.[10] (Fig. 4).

Based on the considerations outlined above, we propose the following management algorithm (Fig. 5).

We believe that close collaboration between specialists is essential, as integrating expertise from both fields is necessary to achieve optimal outcomes. When surgical intervention is indicated in both fields, simultaneous combined surgery provides a direct, reliable, and curative strategy, with low morbidity, a low complication rate, and generally rapid recovery. This approach avoids prolonged courses of unsuccessful conservative treatment and facilitates uncomplicated dental reconstruction.

High success rates can be expected when both dental and sinonasal disease are treated; however, the treatment strategies used and the sequence of procedures may vary according to the type of dental disease and the burden of sinonasal symptoms.

CONCLUSIONS

Our study highlights the importance of a multidisciplinary approach involving otolaryngologists and dental specialists in the management of odontogenic sinusitis, emphasizing the high success rate, reliability, and predictability of single-stage combined surgery.

Author contributions: Conceptualization, Investigation (CS, FZ, SA). Data Curation, Formal Analysis, Methodology, Project Administration (CS).

Conflicts of interest: The authors declare no conflicts of interest related to the content of this article.

Funding: The authors declare that this study received no external funding.

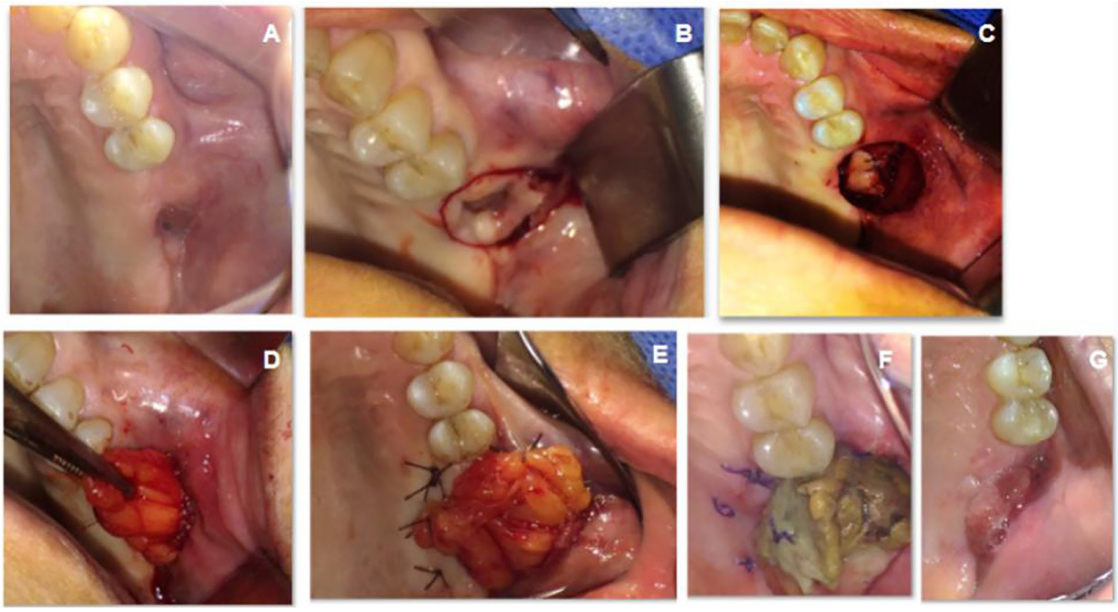

Figure 4. Oral cavity. A: Chronic oroantral fistula. B: Marginal flap design. C: Defect closure with a marginal flap. D: Buccal fat pad dissection. E: Second-layer closure with the buccal fat pad. F: Epithelialization. G: One-month follow-up showing complete epithelialization of the vestibular mucosa..

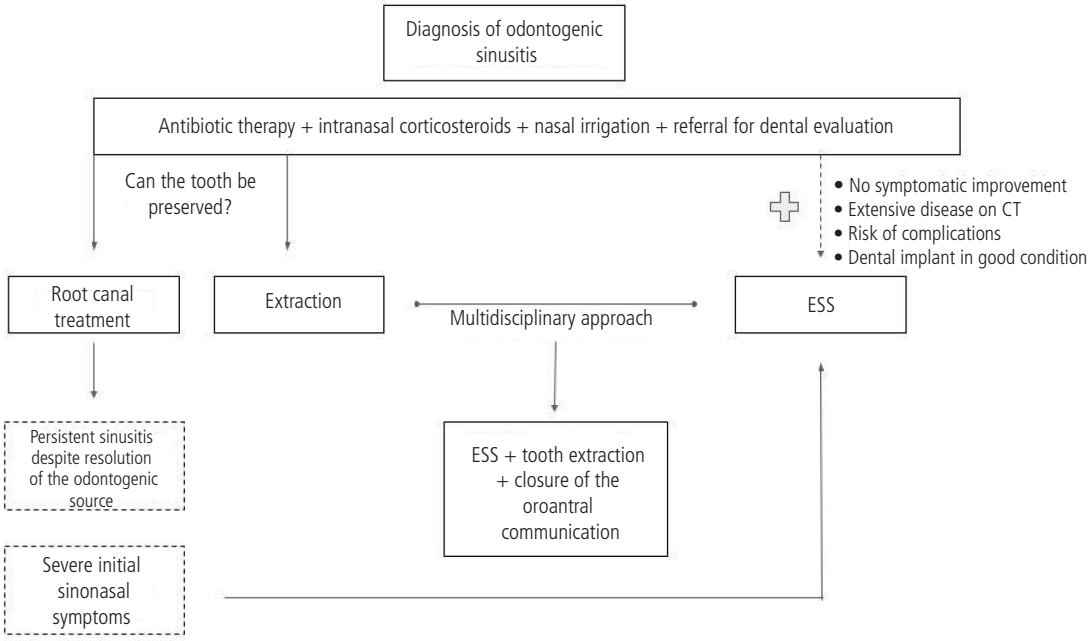

Figure 5. Management algorithm: multidisciplinary approach.

REFERENCES

1. Craig JR. Odontogenic sinusitis: a state-of-the-art review. World J Otorhinolaryngol Head Neck Surg. 2022;8(1):8-15.https://doi.org/10.1002/wjo2.9.
2. De Corso E, Rigante M, Mele DA, et al. Real-life experience in the management of sinonasal complications of dental disease or treatments. J Pers Med. 2022;12(12):2078.https://doi.org/10.3390/jpm12122078.
3. Lin J, Wang C, Wang X, et al. Expert consensus on odontogenic maxillary sinusitis multi-disciplinary treatment. Int J Oral Sci. 2024;16(1):11. https://doi.org/10.1038/s41368-024-00278-z.
4. Harvey R. Dental infection and sinusitis...more common than we think. Darlinghurst: University of New South Wales. Sydney ENT Clinic; 2025 Nov 7 [citado 2026 feb 23]. Disponible en:https://richardharvey.sydneyentclinic.com/2025/11/07/dental-infection-and-sinusitis-more-common-than-we-think/.

5. Yoo BJ, Jung SM, Lee HN, et al. Treatment strategy for odontogenic sinusitis. Am J Rhinol Allergy. 2021;35(2):206-212.https://doi.org/10.1177/1945892420946969.
6. Pannkuk TF, Craig JR, Tušas P, et al. Management of endodontic disease for odontogenic sinusitis. Otolaryngol Clin North Am. 2024;57(6):1119-1138.https://doi.org/10.1016/j.otc.2024.07.002.
7. Mattos JL, Ferguson BJ, Lee S. Predictive factors in patients undergoing endoscopic sinus surgery for odontogenic sinusitis. Int Forum Allergy Rhinol. 2016;6(7):697-700.https://doi.org/10.1002/alr.21736.
8. Kocum P, Šedý J, Traboulsi J, et al. One-stage combined ENT and dental surgical treatment of odontogenic sinusitis: a prospective study. Eur Arch Otorhinolaryngol. 2024;281(3):1347-1356.https://doi.org/10.1007/s00405-023-08332-y.
9. Visscher SH, van Minnen B, Bos RRM. Closure of oroantral communications: a review of the literature. J Oral MaxillofacSurg. 2010;68(6):1384-1391.https://doi.org/10.1016/j.joms.2009.07.044.
10. Kwon MS, Lee BS, Choi BJ, et al. Closure of oroantral fistula: a review of local flap techniques. J Korean Assoc Oral Maxillofac Surg. 2020;46(1):58-65.https://doi.org/10.5125/jkaoms.2020.46.1.58.